

**Anthrax outbreak associated with handling dead meat and contaminated milk,
Sierra Leone, May 2022**

Authors: Umaru Kapr Dumbuya^{1†}, Adel Hussein Elduma^{2,3 †*}, Ibrahim Gassama¹, Babatunde Duduyemi⁴, Umaru Sesay², Kassim Kamara², Amara Alhaji Sheriff ^{2,3}, Anna Jammeh^{2,3}, James Squire⁵, Sheriff Chernor Jalloh¹, Gebrekrstos Negash Gebru^{2,3 †}

Affiliations

¹ Ministry of Health, Sierra Leone

² Sierra Leone Field Epidemiology Training Program

³ African Field Epidemiology Network

⁴ University of Sierra Leone Teaching Hospitals Complex

⁵ National Public Health Agency

Authors:

Umaru Kapr Dumbuya, umarkaydurz@gmail.com, Ibrahim Gassama, ibrahingssm@gmail.com,

Babatunde Duduyemi, babsdudu@yahoo.com, Kassim Kamara, kassim10915@gmail.com

Amara Alhaji Sheriff, amaraalhaji1970@gmail.com, Umaru Sesay, sesayumaru4@gmail.com;

Anna Jammeh, ajammeh@afenet.net, Sheriff Chernor Jalloh, drstephenfornie@gmail.com;

James Squire, jmssquire@yahoo.com; Adel Hussein Elduma, ahussein@afenet.net; Gebrekrstos

Negash Gebru, ggebru@afenet.net,

Corresponding author:

Adel Hussein Elduma

Sierra Leone Field Epidemiology Training Program

African Field Epidemiology Network,

Freetown, Sierra Leone,

Email: ahussein@afenet.net

November 2024

DOI: <https://dx.doi.org/10.4314/sljbr.v15i2.4>

Abstract

Anthrax is a zoonotic disease that is of public health concern. On May 5, 2022, the National Surveillance Program received a notification of suspected human anthrax cases from Karene District, Sierra Leone. We investigated to confirm the diagnosis, determine the magnitude, and identify possible risk factors. We developed an anthrax outbreak case definition, reviewed health facility records, and interviewed cases and their families to collect demographics, clinical, and exposure data. Swab samples were collected and sent to the laboratory for confirmation using real-time PCR. We conducted an active case search, line-listed contacts, and monitored for 14 days. Five cases of cutaneous anthrax were reported; three were below ten years old, three were females—all cases presented with fever, and three presented with skin lesions and body weakness. Four cases developed symptoms after consuming meat from sheep, which died of unknown causes in Karene District. One case from Kailahun District drank milk bought from a female vendor with skin lesions suggestive of anthrax. We identified 27 contacts with no additional cases detected; none of the contacts developed symptoms, and none of the cases died. This investigation confirmed an anthrax outbreak among humans. Possible epidemic sources are processed meat from dead sheep and the handling of contaminated milk. We recommend strengthening human and animal surveillance.

Keywords: Cutaneous anthrax, Zoonoses Disease, Outbreak, Humans, Sierra Leone

Introduction

Anthrax is a contagious disease caused by gram-positive bacteria called *Bacillus anthracis*. It is a zoonotic bacterial infection of public health importance. Anthrax can be transmitted between warm-blooded animals and humans through contact with infected animals or consumption of animal products contaminated with anthrax. The infection can spread through respiratory, gastrointestinal, or cutaneous exposure.

Respiratory exposure can occur when inhaling anthrax spores, while gastrointestinal exposure can occur when a person eats uncooked or undercooked meat infected with the bacteria. Cutaneous exposure happens when a person comes into contact with infected livestock during handling or slaughtering. (Carlson *et al.*, 2019).

According to the U.S. CDC, the incubation period for cutaneous anthrax

November 2024

is usually 1–7 days after exposure, but it can range from 0.5–17 days. In rare cases, symptoms can develop up to 42 days after exposure. (Kamal *et al.*, 2011). People infected with anthrax may experience fever, ulcers, abdominal pain, diarrhea, and vomiting. Prompt treatment is essential, as the case fatality rate can range from 20% to 40%. (*Bacillus anthracis (Anthrax)*, 2014). Vaccination of livestock and proper disposal of infected carcasses are essential to prevent and control anthrax. (Ashenefe Wassie *et al.*, 2022). Globally, around 1.83 billion people and 1.1 billion livestock are at risk of anthrax infection, with between 20,000 and 100,000 people being infected with the disease annually. The majority of these infections occur in impoverished rural areas. (Carlson *et al.*, 2019, p. 1). In Sub-Saharan Africa, the true prevalence of anthrax infection remains unknown due to weak

DOI: <https://dx.doi.org/10.4314/sljbr.v15i2.4>

surveillance systems (Muturi *et al.*, 2018, p. 1). The government implemented health interventions in Sierra Leone after the 2014-2016 Ebola outbreak, including training of health personnel and improving laboratory testing capacity (Leone S, 2015). Despite the implementation of measures such as the formation of health committees and training of community health volunteers to enhance community health promotion, outbreaks of zoonotic diseases, including anthrax, persist. In 2018, Sierra Leone reported four cases of cutaneous anthrax that were detected at Wesleyan Hospital in Kamakwie town, located in Karene District (Adeleke, Fasomoyin and Adekunle, 2020). In February 2022, an anthrax outbreak was confirmed following an alert of the sudden deaths of 204 animals, including cattle, sheep, and goats, in Bundulai Chiefdom, Port Loko November 2024

District, in the northwest region of Sierra Leone. As more deaths occurred during the period in the district, on May 15th, 2022, the Sierra Leonean government, through the Ministry of Agriculture, confirmed an outbreak of anthrax among animals. Between May 15th and May 20th, 2022, the surveillance units of two Districts (Karene and Kailahun) received alerts of suspected cases of cutaneous anthrax in humans. The rapid response teams in both districts and the Sierra Leone Field Epidemiology Training Program (FETP) trainees were deployed to investigate the cases.

Materials and Methods

Study Design and Period

The medical teams quickly isolated individuals with suspected cases, collected samples, and sent them to the National Central Public Health Reference Laboratory (NCPHRL) for thorough testing. The District Rapid DOI: <https://dx.doi.org/10.4314/sljbr.v15i2.4>

Response Team (DRRT) made initial diagnoses based on clinical assessments obtained through interviews. We have confirmed cases of cutaneous anthrax in potential human cases identified through active surveillance. We used qPCR, which targeted the chromosome and two virulent plasmids at the 34 Military Hospital, Chinese Laboratory Freetown. The investigation's primary objectives were to validate the diagnoses, assess the scale of the outbreak, identify the potential source of infection, and implement effective measures to contain the spread of the disease.

Study Areas

An anthrax outbreak has been reported in two communities in Sierra Leone. The first community is Manutheneh in the Buya Chiefdom, located in the Karene District in the Northwest region. The second community is Bendu in the November 2024

Kailahun District in the Eastern region. These areas share international boundaries with Guinea (Figure 1). The primary economic activities in these districts include farming, cattle rearing, and petty trading. Karene District, established in 2018, is one of the two new districts in Sierra Leone. Both Districts are far from the national capital city, Freetown, with Karene District being 268.9km away and Kailahun District being 423.5km away. Additionally, both Districts have the laboratory capacity to conduct tests on samples suspected of anthrax.

Anthrax case definition

A suspected case: is defined as someone who lives in Karene or Kailahun or has travelled to these Districts since March 2022 and has developed an acute onset of symptoms. The symptoms start with a raised bump on the skin, which then

progresses over 1 to 6 days from a popular through a vesicular stage to a depressed black eschar, accompanied by swelling ranging from mild to extensive.

A confirmed case: is an individual with the characteristic eschar tested positive for *Bacillus anthracis* in a blood or skin swab.

Using the case-based investigation provided by the Ministry of Health, we collected demographic, clinical, and travel history data. We interviewed case patients and their families and reviewed medical records at the health facilities where the cases were reported. Additionally, we carried out active case searches at the health facility and in the community to identify any additional cases.

A contact case: is defined a contact as any person who experienced anthrax symptoms within 1-3 days of exposure to a confirmed or probable case or
November 2024

within 14 days after the onset of symptoms of a probable or confirmed case. Identified contacts were listed and followed up for 14 days.

Laboratory investigation

We collected five blood and skin swab samples from patients with suspected cutaneous anthrax lesions. These samples were carefully gathered by laboratory technicians and sent to the National Central Public Health Reference Laboratory by our laboratory technicians. To confirm the suspected cases, we used a polymerase chain reaction (PCR) method that targeted both the chromosome and two virulent plasmids.

The specific primers used in the PCR test were: rpoB-S:

CCACCAACA_gTA_gAAAAT_gCC; rpoB-

R: AAATTTCA_gTTTCT_gATCT,

rpoB-TM (probe):

ACTT_gT_gTCTC_gTTTCTT_gATCCAA

AgC_g.

Case search

We conducted thorough case searches to identify suspected cases promptly and accurately reviewed medical records from various healthcare facilities, including District hospitals, Chiefdom health centres, and village clinics. Additionally, the District Rapid Response Team (DRRT) conducted door-to-door visits in the affected villages to locate individuals who may have been exposed and their close contacts. Since May 2022, it has been mandatory for medical institutions and clinics at all levels in the district to report any suspected cases daily. Through proactive surveillance, laboratory tests discovered and confirmed three suspected cases. In total, the outbreak encompassed five instances.

Case management

We provided antibiotics to treat the patient's medical conditions and offered preventive treatment to individuals who

had close contact with them. Additionally, we took measures to decontaminate the animal reservoir, which was identified as the potential source of the infection.

Ethical considerations

"The activity is part of the response to a public health emergency and involves routine notification and investigation of epidemic-prone diseases. It is not considered human-subject research. Patients and their families were informed that their participation is voluntary and can be declined without any consequences. No personally identifiable information was shared with any other parties except for the investigators. The case patients and their families provided verbal consent to collect samples and conduct interviews."

Results

During the outbreak, five individuals were affected, three females and two males, ranging in age from 2 to 37. The cases were reported in the Karene District (four cases) and the Kailahun District (one case). Four of the five cases had direct contact with sheep and goat meat that had died of unknown causes, while the remaining case was infected through contaminated milk. All affected individuals initially presented with a rash that later progressed into ulceration with a central area of eschar. The ulcers appeared one to three days after the onset of the rash and were accompanied by symptoms such as low-grade fever, swelling around the affected area, fatigue, weight loss, and loss of appetite. Most of the ulcers were located on the hands and thighs. The hospitalization period for the affected individuals ranged from 14 to 20 days, November 2024

and fortunately, there were no fatalities recorded. It's worth noting that between the 15th and 2nd of June 2022, the districts of Karene and Kailahun identified a total of five cases of cutaneous anthrax (Figure 2).

Demographic and Clinical Characteristics of the Cases

Case patient one: On May 10, 2022, an 8-year-old female was admitted to the Manutheneh health facility. She resided with her relatives in the Buya Chiefdom, approximately 60 miles northwest of Kamakwie in the Karene District. Her caregivers were farmers who raised cattle, and in this instance, they handled and consumed the meat of deceased sheep. Four days later, the patient started experiencing symptoms including fever, rashes with vesicles and pustules, swelling in the jaw, loss of appetite, and overall body weakness.

The patient had no prior history of experiencing similar symptoms, allergies, or insect stings. There were no accompanying symptoms such as coughing, breathing difficulties, vomiting, or diarrhoea. None of the family members she lived with had ever experienced similar symptoms. The patient had never been admitted to the hospital before. Upon examination, the patient displayed swelling in the left leg, along with a 2cm ulcer with a black eschar at the centre. The surrounding skin was swollen and painful. Swelling of the upper and lower lips was also observed, with the lips deviating towards the affected area. A swab sample was collected and sent to the laboratory for testing, which later came back positive for anthrax through PCR testing.

The patient received treatment with intravenous ceftriaxone at a dosage of

75mg per kilogram per day, intravenous metronidazole at a dosage of 2.5mg per kilogram per dose three times daily, and povidone-iodine wound dressing. Additionally, the individuals in close contact with the patient were prescribed Ciprofloxacin at a dosage of 500mg and doxycycline capsules at a dosage of 100mg, both to be taken twice daily for two weeks. No alternative diagnoses were considered. The timeline indicates that the index case experienced symptoms beginning on May 9, 2022. However, there appears to be a discrepancy as the case was reported to the clinic on May 7, which is before the onset of symptoms.

Case patient two: On May 10, 2022, a four-year-old female living with a family involved in cattle rearing and farming showed symptoms suggestive of anthrax. These symptoms included fever, skin lesions, loss of appetite,

weight loss, and general body weakness. She also had ulcers on her back, swelling on the right side of her face with ocular swelling, and swelling in her right upper arm. The ulcers initially appeared as painless rashes about the size of reddish pimples. Within two days, a well-circumscribed ulcer measuring about 2.5cm with a dark centre and sloughs at the periphery developed. The patient had consumed dead sheep meat, similar to another individual who had also fallen ill after eating meat from dead sheep. Initially, the patient received traditional home remedies, but her condition did not improve. After the onset of symptoms, she was treated with ciprofloxacin and doxycycline. On May 16, 2022, a rapid response team visited the health facility, collected swab samples, and sent them to the laboratory for testing. The laboratory confirmed that the patient had tested November 2024

positive for anthrax by PCR. The patient eventually recovered and was discharged after fourteen days.

Case patient three: A 37-year-old female who worked as a farmer lived in a village where three cases of anthrax had been confirmed. She lived near the first two cases and had processed and consumed meat from dead sheep and goats, some of which she had sold in the village. Three days after handling and eating the meat on May 12, 2022, she began experiencing symptoms such as fever, skin lesions, loss of appetite, weight loss, weakness, body rash, and pain and swelling around her right leg. Her left hand later developed into a painful ulcer, indicating a possible anthrax infection. The case began with the use of traditional herbal treatment. This individual was discovered during an active search for cases in communities carried out by the rapid

response team. The patient was isolated and suspected of having a cutaneous anthrax infection. A swab sample was taken and sent to the laboratory for testing. The individual developed multiple dark skin lesions on the upper and lower extremities, as well as an ulcer on the right leg with visible dried blisters and scales. Subsequently, the patient was treated with ciprofloxacin and doxycycline, which led to positive clinical outcomes. The sample that was collected tested positive for anthrax on May 22, 2022. The patient made a full recovery and was discharged.

Case patient four: Was a two-year-old male living in Manutheneh Village Buya Chiefdom, about 60 miles northwest of Kamakwie in the Karene District. He resided with his parents and was the youngest of three children. On May 14, 2022, the patient's mother took him to
November 2024

the Manumtheneh health facility due to various symptoms, including fever, skin lesions, loss of appetite, weakness, and a history of ulcer on the thigh following immunisation. The patient developed a rash at the injection site on the lateral aspect of his right thigh, which started small but progressively increased, forming an abscess and an ulcer with a central area of eschar. The rash also appeared around his neck and became ulcerated within three days. The ulcer was painless and had a central area of eschar with no associated purulent discharge. Additionally, the patient developed a high-grade and intermittent fever.

His immunisation was current; he was the youngest of three children born in a monogamous family setting. His elder siblings had a history of childhood illnesses, but no other family members had similar symptoms. During the examination, the patient was pale,
DOI: <https://dx.doi.org/10.4314/sljbr.v15i2.4>

febrile, and had an enlarged cervical lymph node. The nurse observed a poorly defined ulcer on the middle half of the lateral aspect of the right thigh, which was about 2 cm in diameter. The ulcer had a central area of dark eschar and slight hypopigmentation of the surrounding skin. The nurse discovered that the patient tested negative for malaria. On May 16, 2022, a swab sample was collected and sent to the laboratory for testing. The patient was treated with oral paracetamol, haematinics, and ciprofloxacin. On May 22, 2022, the sample tested positive for anthrax by PCR retest, conducted on the same day and returned positive for anthrax. The patient fully recovered and was subsequently discharged.

Case patient 5: was a 25-year-old male residing in the Kono Bendu community in the southern part of the Kailahun District. On May 7, 2022, he started experiencing symptoms while in November 2024

Freetown. The next day, he sought treatment for a sore throat and skin infection at a nearby health facility. On May 14, he returned to Kono Bendu village. The following day, he visited a health facility, presenting with multiple symptoms, including blisters on his skin (especially on his upper and lower limbs), high-grade fever, muscle aches, cough, and loss of appetite. He also experienced nausea without vomiting. The attending physician observed dark skin lesions on the upper and lower extremities, with visible dried blisters and scales. During auscultation, the physician detected mild lung crackles, wheezing, and swollen lymph nodes under both armpits. Malaria and HIV tests were negative, leading to a suspicion of cutaneous anthrax infection.

The nurse in charge notified the District Health Management Team (DHMT) on the same day. The rapid response team DOI: <https://dx.doi.org/10.4314/sljbr.v15i2.4>

collected swab samples and sent them to the laboratory for testing. On May 16, 2022, the sample tested positive for anthrax by PCR. The case was treated with ciprofloxacin, doxycycline, and other adjuvant drugs and the patient was isolated. The case fully recovered on June 2, 2022.

Record review, active case search, and contact tracing

We thoroughly examined records, actively searched for cases, and performed contact tracing during our investigation. Our review encompassed the health facility register, rumour logbook, case-based form, and District database. After a comprehensive search, we uncovered no additional cases in these records. However, upon conducting community-level investigations, we came across one reported case (referred to as case-patient three) from the Karene District November 2024

during an active case search conducted by the rapid response team. Subsequently, we meticulously identified and listed 27 contacts and closely monitored them. Fortunately, none of the contacts exhibited any symptoms indicative of anthrax infection.

Epidemiological findings

Four of the reported cases in Karene District were from the same village and had been in contact with dead sheep and goat meat. The fifth case was reported from Kailahun District and had no connection with those reported in Karene District. None of the patients had travelled to a region with an ongoing anthrax outbreak to or before the outbreak.

Discussion

An investigation has confirmed an outbreak of cutaneous anthrax in the DOI: <https://dx.doi.org/10.4314/sljbr.v15i2.4>

Karene and Kailahun Districts of Sierra Leone. There has been a total of 5 confirmed cases, with four patients residing in the same village and consuming dead meat from sheep and goats around the same time. The fifth patient, from Kailahun District, consumed milk purchased from a vendor in Freetown suspected of being infected with bacilli anthracis. Fortunately, no deaths were reported during the anthrax outbreak, likely due to the rapid response of the healthcare workers and the swift treatment provided to the patients. Cutaneous anthrax can be fatal if left untreated, but all the case patients received timely treatment.

The district surveillance team was immediately notified after the first case was detected in a health facility, showcasing the improved capacity of the Sierra Leone public health system

November 2024

to prevent, detect, and respond to public health priority disease outbreaks. This could be attributed to the presence of trained healthcare workers in the Ministry of Health, who can promptly detect and notify any diseases or events of public health concern, including anthrax. The findings suggest that contact with dead sheep and goats, along with consumption or contact with milk contaminated with *Bacillus anthracis*, may be the primary source of exposure.

Our findings were consistent with a study conducted in Uganda, which found that handling the carcass of a cow that died suddenly was associated with cutaneous anthrax (Kisaakye *et al.*, 2020). Additionally, anthrax infection resulted from contact with and consumption of anthrax-infected carcasses in Zimbabwe (Gombe *et al.*, 2010). Evidence from the literature has shown that contamination of milk with

DOI: <https://dx.doi.org/10.4314/sljbr.v15i2.4>

Anthrax spores poses the greatest risk and can be a source of anthrax infection (Ba.xter R.G, 1977). Adeleke et al. found that residents in the Karene District contracted anthrax from contaminated milk and poultry (Adeleke, Fasomoyin and Adekunle, no date). A study in the Ethiopia-Amhara region found that an anthrax outbreak was caused by slaughtering and selling infected animals to the village (Ashenefe Wassie *et al.*, 2022). Despite the existence of the Sierra Leone Food and Food Safety Act, 2017, which prohibits the distribution of animal products, including meat and milk without sanitary certification, it is still common practice to distribute these products without certification (Gouvernement of Sierra Leone, 2017). In Sierra Leone, particularly in the affected Districts, farmers commonly sell meats and milk from dead animals. This is likely due to the poor economic

November 2024

conditions that force residents to consume these animal products. Additionally, farmers may try to minimize their losses by selling these products. To reduce the risk of eating contaminated animal products, the Ministry of Health can enforce the Food Safety Act more strictly. Despite the consumption of dead meat, there were no cases of gastrointestinal anthrax reported during the outbreak. The study revealed that the cases reported in Karene District and one case in Kailahun District were not linked epidemiologically and had no contact history with anthrax patients. One limitation of this study was that we were unable to determine whether gastroenterology exposure occurred or not. Additionally, no animal samples were tested during this investigation. Moreover, individuals who may have been infected but showed mild symptoms, as well as those who had

DOI: <https://dx.doi.org/10.4314/sljbr.v15i2.4>

moved away from the infected areas, were not identified during our investigations, which may lead to an underestimation of the total number of cases detected and reported.

Conclusion

After conducting an investigation, it has been confirmed that an anthrax outbreak has occurred in Sierra Leone, marking the first instance since 2018. The potential cause of this epidemic is believed to be the processing and consumption of meat from sheep and goats that died from unknown causes. In response, we have taken measures to strengthen the surveillance system and ensure the proper disposal of animal carcasses through disinfection, burning, and burial. Enhancing human and animal surveillance systems is crucial to promptly detecting future outbreaks. As a precaution, people are advised to refrain from consuming meat

from deceased animals or unknown sources.

Acknowledgements

We acknowledge the Ministry of Health, the District Health Management Team in Kailahun and Karene Districts, the African Field Epidemiology Network, and the Sierra Leone Field Epidemiology Training Program

Competing interest

The authors declare no conflict of interest.

Author's contribution

(1) conception and design of the study or analysis and interpretation of data and

(2) drafting the paper or substantially revising it and

(3) approving the final version to be published and

(4) accepting accountability for all aspects of the work.

- Umaru Kapr Dumbuya, Ibrahim Gassama, Adel Hussein Elduma, Gebrekrstos Negash Gebru (1), (2), (3) and (4)
- Kassim Kamara, Amara Alhaji Sheriff, Babatunde Duduyemi, Anna Jammeh, Umaru Sesay (2), (3) and (4)

- James Squire, Sheriff Chernor Jalloh (3) and (4)

References

Adeleke, A.A., Fasomoyin, O.O. and Adekunle, K.A. (2020) 'Cutaneous Anthrax in Kamakwie, Karene District, Northern Sierra Leone'.

Adeleke, A.A., Fasomoyin, O.O. and Adekunle, K.A. (no date) 'Cutaneous Anthrax in Kamakwie, Karene District, Northern Sierra Leone', *Journal Of Case Reports* [Preprint].

Ashenefe Wassie, B. *et al.* (2022) 'First PCR Confirmed anthrax outbreaks in Ethiopia—Amhara region, 2018–2019', *PLOS Neglected Tropical Diseases*. Edited by O.S. Fedorova, 16(2), p. e0010181. Available at: <https://doi.org/10.1371/journal.pntd.0010181>.

Bacillus anthracis (Anthrax) (2014) *Johns Hopkins Center for Health Security*. Available at: <https://www.centerforhealthsecurity.org/our-work/publications/bacillus-anthraxis-anthrax-fact-sheet> (Accessed: 14 March 2023).

Baxter R.G (1977) 'ANTHRAX IN THE DAIRY HERD', *Journal of the South African Veterinary Association*, 48(4), pp. 293–295.

Carlson, C.J. *et al.* (2019) 'The global distribution of *Bacillus anthracis* and associated anthrax risk to humans, livestock and wildlife', *Nature Microbiology*, 4(8), pp. 1337–1343. Available at: <https://doi.org/10.1038/s41564-019-0435-4>.

Gombe, N. *et al.* (2010) 'Risk factors for contracting anthrax in Kuwirirana ward, Gokwe North, Zimbabwe', *African Health Sciences*, 10(2), pp. 159–164.

Government of Sierra Leone (2017) 'The Food and Feed Safety Authority Act'. Available at: https://www.parliament.gov.sl/uploads/bill_files/The%20Food%20and%20Feed%20Safety%20Authority%20Act,%202017.pdf.

Kamal, S. *et al.* (2011) 'Anthrax: an update', *Asian Pacific Journal of Tropical Biomedicine*, 1(6), pp. 496–501. Available at: [https://doi.org/10.1016/S2221-1691\(11\)60109-3](https://doi.org/10.1016/S2221-1691(11)60109-3).

Kisaakye, E. *et al.* (2020) 'Outbreak of Anthrax Associated with Handling and Eating Meat from a Cow, Uganda, 2018', *Emerging Infectious Diseases*, 26(12), pp. 2799–2806. Available at: <https://doi.org/10.3201/eid2612.191373>.

Leone S (2015) 'National Ebola Recovery Strategy for Sierra Leone'. Available at: https://ebolaresponse.un.org/sites/default/files/sierra_leone_recovery_strategy_en.pdf.

Muturi, M. *et al.* (2018) 'Recurrent Anthrax Outbreaks in Humans, Livestock, and Wildlife in the Same Locality, Kenya, 2014–2017', *The American Journal of Tropical Medicine and Hygiene*, 99(4), pp. 833–839. Available at: <https://doi.org/10.4269/ajtmh.18-0224>.

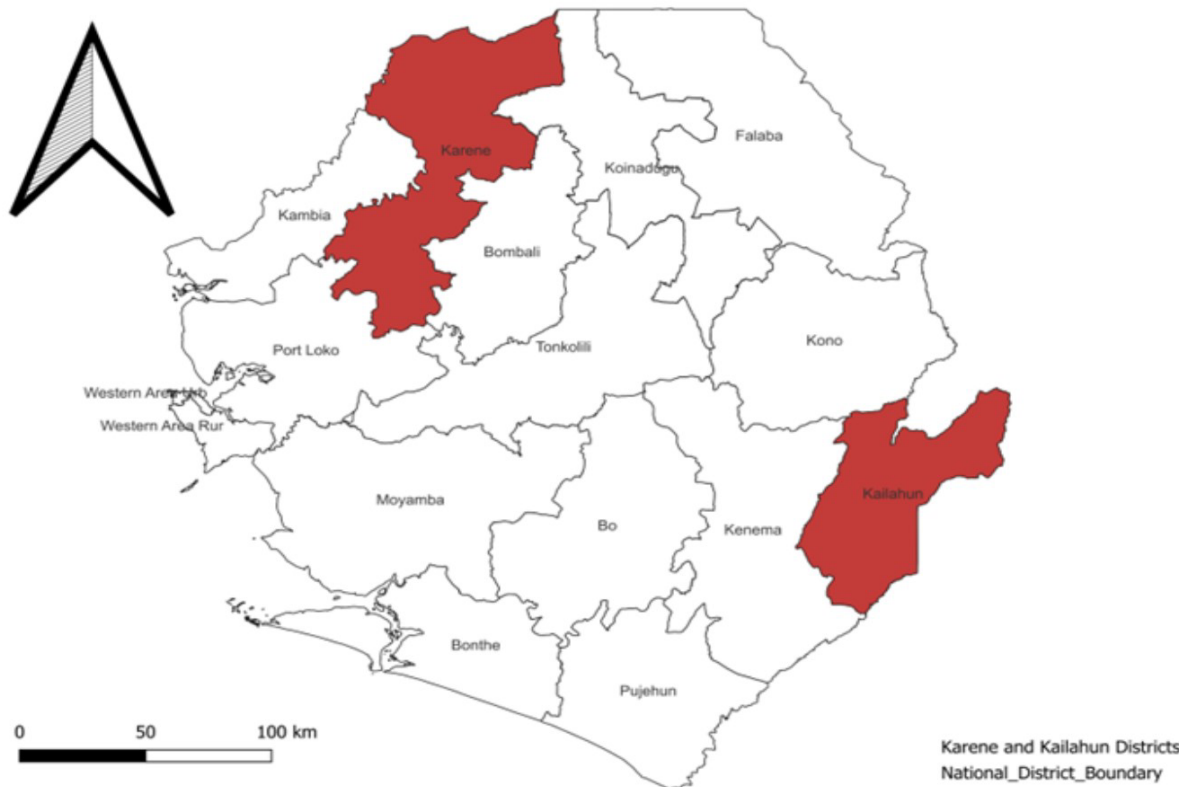


Figure 1: Map of Sierra Leone with outbreak areas highlighted, 2022

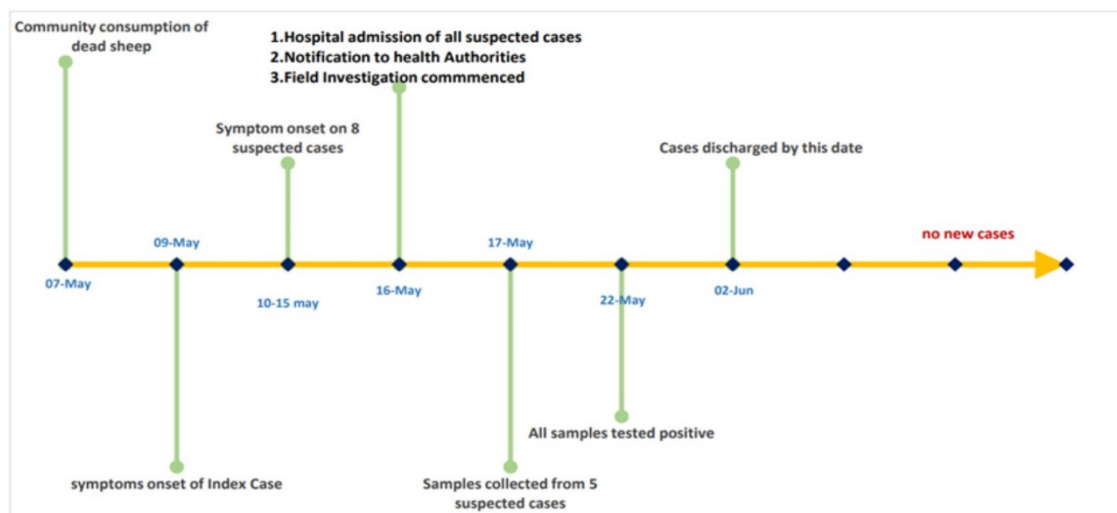


Figure 2: Time sequence of anthrax cases in Sierra Leone, 2022